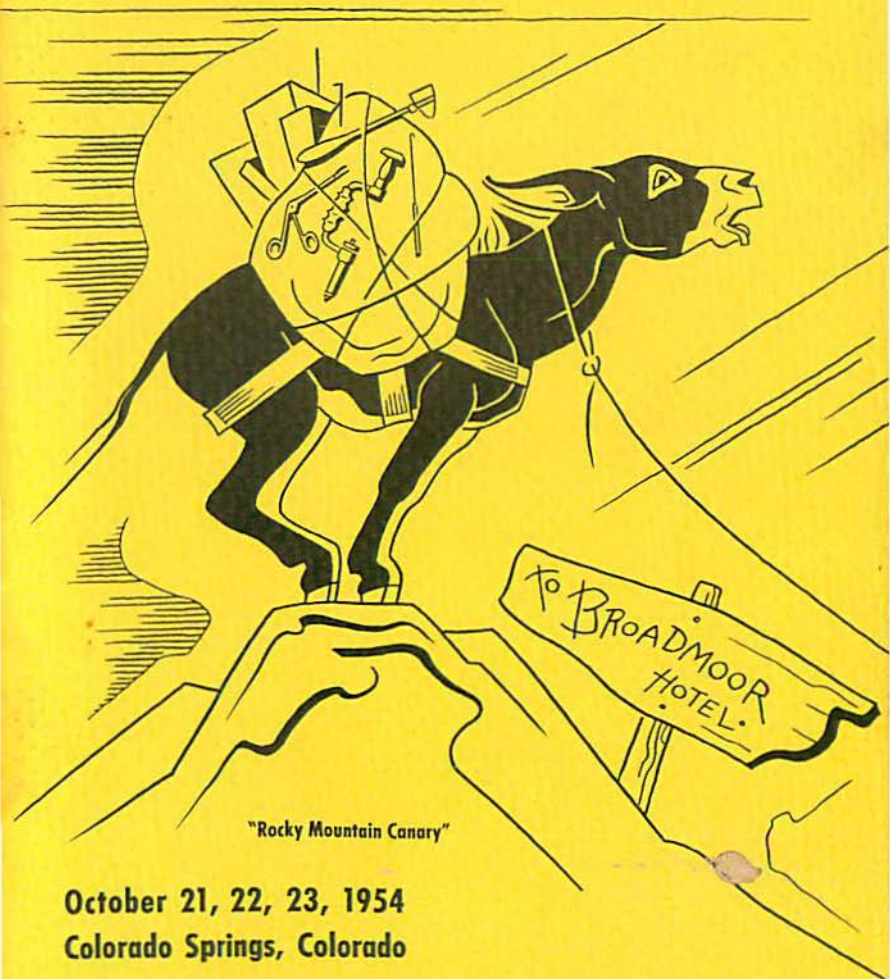


# THE AMERICAN ACADEMY OF NEUROLOGICAL SURGERY


Program of the  
SIXTEENTH ANNUAL MEETING



"Rocky Mountain Canary"

October 21, 22, 23, 1954  
Colorado Springs, Colorado





The American Academy of  
Neurological Surgery

*Sixteenth Annual Meeting*



THE BROADMOOR  
COLORADO SPRINGS, COLORADO

*October 21, 22, 23, 1954*

★ ★ ★

PROGRAM COMMITTEE:

Dr. William H. Sweet, *Chairman*

Dr. Edwin B. Boldrey

Dr. Hannibal Hamlin

THURSDAY, OCTOBER 21, 1954

9:00 a.m.—OPENING OF MEETING

DR. RUPERT B. RANEY, *President*

9:15 a.m.-11:00 a.m.—SCIENTIFIC SESSION

1. THE USE OF IMPLANTED INTRACEREBRAL ELECTRODES FOR RELIEF OF PAIN.

J. LAWRENCE POOL, M.D., AND WILLIAM K. CLARK, M.D.

A brief report on five cases subjected to deep frontal stimulation with implanted electrodes according to the Heath-Tulane method will be given. Pain relief and physiological effects, as well as changes in steroid chemistry, et cetera, will be described.

2. NEUROMECHANISMS OF THE STRESSED STATE.

ROBERT W. PORTER, M.D., PH.D.

Los Angeles, (by invitation)

The relationship between various hormonal and neural factors which interact at the hypothalamic level to influence anterior pituitary function during stress was studied. It has been shown that an intact hypothalamus is essential for the pituitary-adrenocortical response to acute stress stimuli and can be activated through neural or neuro-endocrine pathways. Furthermore, the response of the hypothalamus to the stressor agent is modified by facilitatory and inhibitory factors of both neural and hormonal origin. Other pituitary functions appear to be influenced by these stress-induced hypothalamic alterations as well. The manner in which the adenohipophysis is stimulated by the hypothalamus has not been definitely established.

3. EXPERIMENTAL STUDIES OF TRIGEMINAL NERVE STIMULATION.

ROBERT B. KING, M.D.

St. Louis, (by invitation)

Electrophysiologic investigations of the trigeminal nerve, gasserian ganglion and associated medullary connections are few. Experimental studies of this pain pathway in lower animals and monkeys have been undertaken preliminary to limited investigations of the problem in man.

In the hemidecorticate cat with Anectine and artificial respiration, bipolar recording have been made from the intact second division of the trigeminal nerve in the middle fossa, from the gasserian ganglion, from the trigeminal sensory root and from the medulla using oscillographic techniques. Following cutaneous

## NOTES

and peripheral nerve stimulation features of the initial response have been noted. Characteristically there were also prolonged short duration (approximately one millisecond) multiple discharges recorded from the region of the ganglion and more proximal elements of this pathway. Antidromic condition was noted. Strychnine applied topically at the ganglion caused but little change in these potentials. Section of the root or the descending tract of the trigeminal nerve may alter portions of the recorded potentials in the gasserian ganglion following cutaneous stimuli.

#### 4. EFFECT OF GLOSSOPHARYNGEAL RHIZOTOMY ON THE FUNCTION OF THE CAROTID SINUS: EXPERIMENTAL AND CLINICAL OBSERVATIONS.

H. THOMAS BALLANTINE, JR., M.D., JOHN H. DREW, M.D.,  
JOHN H. CURRENS, M.D., AND MANDEL E. COHEN, M.D.  
(the last three by invitation)

Three monkeys tested immediately after both IXth nerves had been cut did not show (a) the usual increase in rate and depth of respiration following sodium cyanide administration, nor (b) the usual drop in blood pressure after intravenous protoveratrine; both reactions had occurred just prior to the rhizotomies.

One patient tested months after two-stage intracranial bilateral glossopharyngeal rhizotomy also failed to show the expected responses to protoveratrine and sodium cyanide.

These data suggest that the effects on respiration and blood pressure of these drugs are probably related to carotid sinus function, relayed through the IXth nerves.

#### *Discussion:*

ALFRED UIHLEIN, M.D.

11:00 a.m.—COFFEE

11:15 a.m.-1:30 p.m.—SCIENTIFIC SESSION

#### 5. SURGERY AIDED BY HYPOTHERMIA.

HENRY SWAN, M.D.

Professor Surgery and Chairman of the Department  
of Surgery, University of Colorado Medical School  
(by invitation)

#### 6. EXPERIMENTAL OBSERVATIONS ON "PSYCHOSOMATIC" MECHANISMS.

JOHN D. FRENCH, M.D., ROBERT W. PORTER, M.D., PH.D.,  
E. B. CAVANAUGH, AND R. L. LONGMIRE  
(the last three by invitation)

Experimental assessment has been made of factors involved in the development of visceral abnormalities resulting from artificially induced stressful situations. Discrete mechanisms through which

NOTES



(1) disturbed function, (2) acute lesions, (3) focal chronic abnormalities, could be induced in the stomach by destructive or excitatory measures applied to the brain are described. The application of these experimental observations to the problem of "psychosomatic" disease is discussed.

## 7. THE RHINENCEPHALON IN MAN: OBSERVATIONS IN LIMITED LOBOTOMIES.

WILLIAM B. SCOVILLE, M.D.

In the course of carrying out undercutting of the orbital cortex and ablations of various portions of the medial temporal lobe and cingulate gyrus, certain observations and conclusions have been made and previously reported, concerning the gross physiologic functions of the limbic lobe in man. Recent observations on the physiology of the rhinencephalon in man warrant another report. Past work has shown that stimulation and ablation of the cingulate and orbital cortices have caused little physiologic changes. Stimulation of the uncus region has shown extreme sensitivity with seizures, loss of consciousness and respiratory arrest. Bilateral ablations of the hippocampal area have resulted in grave and prolonged loss of recent memory.

Recently, that extreme posterior portion of the orbital cortex extending 1 cm. posterior to the anterior clinoids and involving the subcallosal gyrus, parolfactory area and probable septal nuclei has been undercut in six cases. Physiologic and mental changes have been marked when this area has been involved, including temporary status epilepticus, loss of consciousness, a bizarre confusional state, and marked hyponatremia (104 milliequivalents) without fall in serum chlorides, potassium or  $\text{CO}_2$ . Stimulation of olfactory cortex within our parameters of stimulation has not caused hallucinations of smell nor temporosphenoidal fits.

In conclusion, the rhinencephalon in man appears to have a physiologic sensitivity and importance far removed from its primitive function of smell, and the rhinencephalic portion of the limbic lobe complex appears to play the dominant role in physiologic functions of this complex.

1:30 p.m.—LUNCH

2:30 p.m.—BUSINESS SESSION—Members only.

## NOTES

FRIDAY, OCTOBER 22, 1954

9:00 a.m.-11:00 a.m.—SCIENTIFIC SESSION

8. LATE RESULTS OF TREATMENT OF TRIGEMINAL NEURALGIA BY PARTIAL RHIZOTOMY FROM THE POSTERIOR APPROACH.

EXUM WALKER, M.D., FRANKLIN C. MILES, M.D., AND  
JAMES R. SIMPSON, M.D.

This is a follow-up report of 144 patients who have had partial trigeminal root section by the posterior approach. Of these patients, 56 were re-examined an average of  $4\frac{1}{3}$  years after operation; 80% had remained for practical purposes, pain free; 20% had had some recurrence—none sufficient to require further root section; 31% had no detectable numbness; 48% had no annoying or objectionable numbness; 21% had numbness described as annoying or objectionable; the corneal reflex was abolished in only 11%. The mortality and complications are discussed and an attempt made to present the advantages and disadvantages of partial rhizotomy by the posterior approach.

*Discussion of this and other newer methods  
of treatment of trigeminal neuralgia:*

WALLACE B. HAMBY, M.D.  
HENRY G. SCHWARTZ, M.D.  
ROBERT PUDENZ, M.D.

9. INFARCTION OF THE CEREBELLUM WITH ACUTE OBSTRUCTION OF FOURTH VENTRICLE AND AQUEDUCT: OPERATIVE TREATMENT.

FRANCIS MURPHEY, M.D.  
SAM A. SCOTT, M.D. (by invitation)

Three cases of spontaneous infarction of the cerebellum with acute obstruction of the aqueduct are reported. In two cases there was evidence of polycythemia and in the third, hemoconcentration following burn. Each patient complained of severe headaches followed by nausea and vomiting and after a day or so became unconscious. In two instances a cerebellar abscess was suspected. The diagnosis of posterior fossa lesion was confirmed by ventriculography and in each instance liquefaction of part of one lobe of the cerebellum was found. In each case only the liquefied cerebellum was removed and in one case a secondary operation was necessary to remove more liquefied tissue. In a second instance the patient died suddenly, but autopsy was not permitted. It is believed that a more radical removal of adjacent edematous tissue would have obviated the necessity of the second operation in one case and probably prevented the death of the second patient.

## NOTES

## 10. CEREBELLAR MEDULLOBLASTOMA IN AN ADULT CAUSING SYNDROME OF TUMOR IN THE ANGLE AND EROSION OF PETROUS RIDGE.

JOHN M. MEREDITH, M.D.

The patient was a 33-year-old white male who was first seen in our clinic on July 21, 1953 and discharged August 28, 1953. We thought when first examined that he probably had an acoustic tumor on the left side as shown by deafness in the left ear, facial weakness on the left side and corneal hypesthesia on the left. He also had nystagmus on looking to the left and slight ataxia of the left finger-to-nose and heel-to-shin test. He tended to fall to the left side. He had headache with vomiting for several weeks before being admitted. It was felt by all observers, preoperatively, that he had an acoustic tumor on the left side as deafness had been an initial symptom and caloric tests by the otolaryngology department had suggested a lesion in the left cerebellopontine angle with almost total destruction of left eighth nerve function.

At operation, done in the sitting position, a hemicerebellar exposure was done on the left side and to our surprise the left eighth nerve was perfectly normal as were the ninth, tenth, eleventh and the fifth nerves and the cerebellum seemed normal until an incision was made in a cystic area and eventually a typical medulloblastoma was encountered intrinsically in the left cerebellar hemisphere but must have involved the nerves in the angle rather medialward as laterally in the angle they all seemed perfectly normal. Microscopically, the tumor was a typical medulloblastoma and responded to X-ray therapy in the usual satisfactory fashion.

His wound healed satisfactorily and X-ray therapy was given. The fact that in a 33-year-old patient a medulloblastoma was found in the cerebellum was rather unusual in the first place and the fact that the clinical picture was much more that of an acoustic tumor, that X-rays had shown, preoperatively, *erosion of the left petrous ridge*—makes the case, in our opinion, worthy of a brief report.

## 11. PRE-NATAL OBSTRUCTION OF THE FOURTH VENTRICLE.

DONALD D. MATSON, M.D.

There is a characteristic clinical and roentgenographic appearance when the foramina of Magendie and Luschka fail to develop normally or become obstructed during early embryonic life. A large cyst forms within the posterior fossa causing: (1) failure of development of the mid-line cerebellar structures, (2) flattening of the brain stem, (3) failure of descent of the tentorium with its included venous channels, and (4) non-communicating internal hydrocephalus.

Favorable results from surgical therapy depend primarily on early recognition followed by appropriate procedures to relieve the obstructive hydrocephalus before irreversible brain damage has occurred. The physical, roentgenographic, and surgical features of a number of cases treated in infancy will be reviewed.

## NOTES

12. EPENDYMOMAS OF THE PITUITARY GLAND. REPORT OF THREE CASES.

FRANK H. MAYFIELD, M.D.

Inasmuch as portions of the pituitary gland are of neural origin, it is not surprising that gliomas of this structure should occur. Nevertheless, they are exceedingly rare.

The material for this paper consists of the data of three patients with ependymomas of the pituitary gland, two of which were removed at operation and one was an incidental finding at postmortem.

11:00 a.m.—COFFEE

11:15 a.m.-1:30 p.m.—SCIENTIFIC SESSIONS

13. PREVENTION: THE CURE FOR HEAD INJURIES.

C. HUNTER SHELDEN, M.D., AND ROBERT PUDENZ, M.D.

The increasing morbidity and mortality associated with automobile injuries warrants more detailed consideration by neurosurgeons. The problem of treatment of head injuries has been well standardized, but the problems leading to fatal head injuries have not been given due consideration. A very high percentage of fatal head injuries are avoidable by certain structural changes in the design of motor vehicles. Automobile manufacturers have not been prompted to introduce any new developments, and will not until public opinion becomes strong enough to demand such changes. It may well be within the scope of this organization to stimulate public opinion to the point that these changes may be mandatory.

14. CLINICAL NEUROSURGICAL ASPECTS OF OSTEO-  
LYTIC LESIONS OF THE SKULL.

GEORGE S. BAKER, M.D.

A classification of the surgical lesions of the human skull as well as the methods used to control the lesions will be stressed.

*Discussion:*

FRANCIS MURPHEY

15. INDICATIONS FOR AND RESULTS OF CEREBRAL  
HEMISPHERECTOMY IN INFANTILE HEMI-  
PLEGIA.

WYLIE MCKISSOCK, F.R.C.S.  
(by invitation), to be presented by  
MR. HANKINSON, F.R.C.S.  
(by invitation)

The patients in this group show some degree of spastic hemiparesis usually with loss of cortical sensation and possibly homony-

## NOTES



mous hemianopsia. Most show some degree of mental retardation and the majority suffer from epilepsy. Disordered behaviour, "temper tantrums," commonly accompany the clinical state.

Investigations include skull radiograms, encephalography, which usually show gross dilatation of the ventricle of the affected hemisphere. Radiograms after 24 hours show cyst formation frequently around the Sylvian fissure.

Arteriography is not considered of much value. Electroencephalography has not been particularly helpful. Psychological testing is carried out to obtain as accurate as possible an estimate of the mental age and ability of the patient. The results are much better in those with a relatively high (though subnormal) I.Q. Psychiatric investigation by a competent psychiatrist is also carried out with the patient and relatives to investigate the "temper tantrums."

A description of the criteria for hemispherectomy is presented.

A fairly detailed description of the technique of the operation is given and finally the results of the first 18 cases. The remaining 14 cases have not been followed for a sufficient length of time.

## 16. INTRACTABLE CONVULSIVE SEIZURES WITH INFANTILE HEMIPLEGIA: TREATMENT BY HEMISPHERECTOMY. REPORT OF TWO CASES.

JAMES GREENWOOD, JR., M.D.

A brief report is given of the indications and results of hemispherectomy for intractable seizures. Some of the problems in techniques encountered are summarized, including hemorrhage into the subdural cavity, one instance of aqueduct stenosis, and a rather profound psychological, intellectual regression in one of the three cases. A fourth case in which cortical resection on the normal side resulted in dramatic improvement without hemispherectomy also is summarized.

1:30 p.m.—LUNCH

## NOTES

SATURDAY, OCTOBER 23, 1954

9:00 a.m.-11:00 a.m.—SCIENTIFIC SESSIONS

17. RUPTURE OF CONGENITAL ANEURYSMS OF THE INTERNAL CAROTID INTO THE CAVERNOUS SINUS.

HOMER S. SWANSON, M.D.

This report deals with two instances of the production of a carotid cavernous sinus fistula following the rupture of a congenital aneurysm of the internal carotid artery. These two cases illustrate oddities in the etiology of the cavernous sinus fistulae and suggest the possibility that other fistulae involving other vessels may be secondary to rupture of primary aneurysms into the venous channels.

18. RESULTS OF DIRECT ATTACK ON INTRACRANIAL ANEURYSMS.

STUART N. ROWE, M.D.

JEROME F. GRUNNAGLE, M.D. (by invitation)

A review of approximately 25 cases of aneurysm, attacked intracranially, has revealed a higher mortality than we expected, approximately 33%. However, knowledge gained through painful experience has led to various technical improvements—which we feel are definitely lowering our mortality and should lead to improved results in the future.

The late post-operative results have been excellent with the exception of a few cases in which extensive cerebral damage was produced by associated intracerebral hemorrhage.

*Discussion:*

THOMAS A. WEAVER, M.D.

WALLACE B. HAMBY, M.D.

ALFRED UHLEIN, M.D.

WILLIAM F. MEACHAM, M.D.

19. RESULTS OF DIRECT ATTACK ON INTRACRANIAL ARTERIOVENOUS MALFORMATIONS.

EDWIN B. BOLDREY, M.D.

A series of arteriovenous angiomas is discussed. Some of these have been operated upon and some have not for reasons of refusal of the patient or of decision on part of the surgeon. A discussion of the surgery before and after the use of hypotensive agents is contemplated with reference to values of angiography and pitfalls that have been encountered.

## NOTES

*Discussion:*

THOMAS A. WEAVER, M.D.  
WILLIAM F. MEACHAM, M.D.  
HOMER SWANSON, M.D.  
ALFRED UHLEIN, M.D.

11:00 a.m.—COFFEE

11:15 a.m.-1:30 p.m.—SCIENTIFIC SESSIONS

20. GROUND SUBSTANCE IN INTERVERTEBRAL DISC RUPTURE.

BARNES WOODHALL, M.D.

Clinical and experimental studies have suggested that progressive changes are present in the mucopolysaccharides (hyaluronic acid, chondroitin sulfate, etc.) of the human intervertebral disc during "aging" and during disc "degeneration." These findings have posed the question, does depolymerization of the acid polysaccharides of the ground substance precede acute disc rupture? Or, does an acute disc rupture represent an episode in a chronic degenerative disease of disc tissue?

A more rapid method has been developed for the determination of one of the end products (N-acetylglucosamine) of the enzymatic hydrolysis of hyaluronic acid by testicular and pneumococcal hyaluronidases. Analyses have been completed upon 50 specimens of acute ruptured disc and 18 control specimens of normal human disc. Control studies show a range between 31.85 to 240.77 mgm hyaluronic acid per gram of wet tissue. Analysis of acute ruptured discs shows a range between 0.37 and 14.11 mgm with the majority of the values resting between 0.37 and 1.00 mgm. The significance of these preliminary studies will be discussed.

*Discussion:*

BENJAMIN B. WHITCOMB, M.D.

21. RESECTION OF THE FIRST RIB FOR COSTO-CLAVICULAR SYNDROME: REPORT OF SIX CASES.

HANNIBAL HAMLIN, M.D.

The variable mechanism of costo-clavicular compression is illustrated by several case reviews. Excellent improvement was obtained in all instances by major resection of the first rib. A satisfactory operating technique is described.

*Discussion:*

JOHN RAAF, M.D.  
BENJAMIN B. WHITCOMB, M.D.

## NOTES

## 22. IMMEDIATE LAMINECTOMY FOR TRAUMATIC PARAPLEGIA. REPORT OF FIFTY CASES.

AUGUSTUS McCRAVEY, M.D.

Fifty consecutive cases of traumatic paraplegia were operated as emergency procedures. The operative techniques are described and the late followup results are given.

## 23. SPINAL ARACHNOIDITIS: SOME SURGICAL EXPERIENCES AND RESULTS.

JOHN H. DREW, M.D.

Fourteen cases of spinal arachnoiditis are presented. Possible etiologic factors and pre-operative diagnosis are discussed in terms of history and myelographic study. Individual lesions found throughout the spinal canal varied in extent from single thin bands of scar to massive areas many spinal segments in length.

Twelve cases were verified surgically. Attempts were made to free (at least partially) involved elements of the spinal cord and root, from the scar tissue.

The results of surgical intervention in terms of followup for periods of 4 months to 5½ years are given.

## 24. SPONTANEOUS HEMATOMYELIA AND ANGIOMAS OF THE SPINAL CORD.

GUY ODOM, M.D.

The term "spontaneous hematomyelia" is usually understood as meaning a primary, non-traumatic intramedullary hemorrhage occurring in the absence of preceding symptoms of a spinal cord lesion. It presents a rather typical clinical syndrome consisting of rather sudden onset of severe pain, followed by progressive paraplegia, sensory loss and urinary retention. Three cases are presented in which the etiology was proven (two at operation and one by autopsy) to be due to small intramedullary angiomas. Operation is recommended in this condition as soon as the diagnosis is suspected.

Three cases of extramedullary angiomas are also presented. These lesions may be venous or arteriovenous and all seem to have intramedullary extensions. The clinical course is usually one of long tract signs with progression by a series of apoplectic episodes, followed by improvement, but usually always being left with more residual neurological involvement. The progression is due to thrombosis of vessels or hemorrhage. The presence of skin nevi may suggest the diagnosis. Myelogram usually presents a typical picture. Cases not benefited by operation.

### *Discussion:*

WILLIAM B. SCOVILLE, M.D.

## NOTES



1:30 p.m.—LUNCH

2:30 p.m.—BUSINESS SESSION—Members only.

6:30 p.m.—Cocktails, Broadmoor Hotel  
Members, wives, and guests

7:30 p.m.—Formal Banquet  
Members, wives, and guests

8:30 p.m.

*Presidential Address*

DR. RUPERT B. RANEY

Dancing

1953 - 1954

THE AMERICAN ACADEMY OF NEUROLOGICAL SURGERY

OFFICERS

*President*, RUPERT B. RANEY

*Vice-President*, DAVID L. REEVES

*Secretary and Treasurer*, EBEN ALEXANDER, JR.

*Executive Committee*, RUPERT B. RANEY, *Chm.*

DAVID L. REEVES

EBEN ALEXANDER, JR.

J. LAWRENCE POOL

GEORGE L. MALTBY

HONORARY MEMBERS

1. Dr. Winchell McK. Craig, Mayo Clinic, Rochester, Minnesota.
2. Sir Geoffrey Jefferson, Department of Neurosurgery, The Royal Infirmary, Manchester 13, England.
3. Dr. W. Jason Mixter, Nobska West, Woods Hole, Massachusetts.
4. Dr. R. Glen Spurling, 405 Heyburn Bldg., Louisville 2, Kentucky.

EMERITUS MEMBER

1. Dr. Olan R. Hyndman, Veterans Adm. Hosp., Iowa City, Iowa.

ACTIVE MEMBERS

1. Dr. Eben Alexander, Jr., (Betty) Bowman Gray School of Medicine, Winston-Salem 7, North Carolina.
2. Dr. George S. Baker, (Enid) Section on Neurological Surgery, Mayo Clinic, Rochester, Minnesota.
3. Dr. H. Thomas Ballantine, Jr., (Elizabeth) Massachusetts Gen. Hosp., Boston 14, Massachusetts.

4. Dr. William F. Beswick, 685 Delaware Ave., Buffalo 9, New York.
5. Dr. Edwin B. Boldrey, (Helen) Univ. of Calif. Medical School, San Francisco 22, California.
6. Dr. E. Harry Botterell, (Margaret) Medical Arts Bldg., 280 Bloor St., W., Toronto 5, Ontario.
7. Dr. Spencer Braden, 1304 Hanna Bldg., Cleveland 15, Ohio.
8. Dr. F. Keith Bradford, (Byra) 410 Hermann Professional Bldg., 6410 Fannin St., Houston 5, Texas.
9. Dr. Howard A. Brown, (Dorothy) 384 Post St., San Francisco 8, California.
10. Dr. Harvey Chenault, 200 West Second St., Lexington 6, Kentucky.
11. Dr. Donald F. Coburn, (Max) 221 Plaza Time Bldg., Country Club Plaza, Kansas City 2, Missouri.
12. Dr. Edward W. Davis, (Barbara) 806 S. W. Broadway, Portland 5, Oregon.
13. Dr. Francis A. Echlin, (Letitia) 555 Park Ave., New York 21, New York.
14. Dr. Dean H. Echols, (Fran) 3503 Prytania St., New Orleans, Louisiana.
15. Dr. Arthur R. Elvidge, Montreal Neurological Institute, 3801 University St., Montreal 2, Quebec.
16. Dr. Theodore C. Erickson, (Emily) 1300 University Ave., Madison 6, Wisconsin.
17. Dr. Joseph P. Evans, (Hermene) University of Chicago Clinics, Chicago 37, Illinois.
18. Dr. John D. French, Veterans Administration Hospital, Long Beach 4, California.
19. Dr. James G. Galbraith, (Peggy) 2020 15th Ave., S., Birmingham, Alabama.
20. Dr. Everett G. Grantham, 405 Heyburn Bldg., Louisville 2, Kentucky.
21. Dr. John R. Green, (Georgia) 550 West Thomas Rd., Patio A, Suite 202, Phoenix, Arizona.
22. Dr. James Greenwood, Jr., (Mary) 1105 Hermann Professional Bldg., 6410 Fannin St., Houston 5, Texas.
23. Dr. Wesley A. Gustafson, (Jennie) 700 North Michigan Ave., Chicago 11, Illinois.
24. Dr. Wallace B. Hamby, (Hellyn) 140 Linwood Ave., Buffalo 9, New York.

25. Dr. Hannibal Hamlin, (Margaret) 270 Benefit St., Providence 3, Rhode Island.
26. Dr. Jess D. Herrmann, (Mary Jo) 525 Northwest Eleventh St., Oklahoma City 3, Oklahoma.
27. Dr. Henry L. Heyl, (Katharine) Hitchcock Clinic, Hanover, New Hampshire.
28. Dr. William S. Keith, Toronto Western Hospital, 399 Bathurst St., Toronto 2B, Ontario.
29. Dr. George L. Maltby, (Sim) 203 State St., Portland 3, Maine.
30. Dr. Donald D. Matson, (Dorothy) 300 Longwood Ave., Boston 15, Massachusetts.
31. Dr. Frank H. Mayfield, (Queenee) 506 Oak St., Cincinnati 19, Ohio.
32. Dr. Augustus McCravey, (Helen) 540 McCallie Ave., Chattanooga 3, Tennessee.
33. Dr. William F. Meacham, (Alice) 2122 West End Ave., Nashville 5, Tennessee.
34. Dr. John M. Meredith, (Etta Elizabeth) 1200 E. Broad Street, Richmond 19, Virginia.
35. Dr. Edmund J. Morrissey, (Kate) 450 Sutter St., Suite 520, San Francisco 8, California.
36. Dr. Francis Murphey, (Roder) Suite 525, Physicians & Surgeons Bldg., Memphis 3, Tennessee.
37. Dr. Guy L. Odom, (Suzanne) Duke University—School of Medicine, Durham, North Carolina.
38. Dr. J. Lawrence Pool, (Angeline) 710 W. 168th St., New York 32, New York.
39. Dr. Robert Pudenz, 696 E. Colorado St., Pasadena 1, California.
40. Dr. John Raaf, (Lorene) 1010 Medical Dental Bldg., Portland 5, Oregon.
41. Dr. Aidan A. Raney, (Mary) 1136 W. Sixth St., Los Angeles 17, California.
42. Dr. Rupert B. Raney, (Alta) 1136 W. Sixth St., Los Angeles 17, California.
43. Dr. Theodore B. Rasmussen, (Catherine) Montreal Neurological Institute, 3801 University St., Montreal 2, Canada.
44. Dr. David L. Reeves, (Marjorie) 316 W. Junipero St., Santa Barbara, California.
45. Dr. R. C. L. Robertson, (Marjorie) 411 Hermann Professional Bldg., 6410 Fannin St., Houston 5, Texas.

46. Dr. Stuart N. Rowe, (Elva) 516 Medical Arts Bldg., 3700 Fifth Ave., Pittsburgh 13, Pennsylvania.
47. Dr. Henry G. Schwartz, (Reedy) Dept. of Surgery, Washington Univ., St. Louis 10, Missouri.
48. Dr. William B. Scoville, 85 Jefferson St., Hartford 14, Connecticut.
49. Dr. C. Hunter Shelden, (Betty) 696 E. Colorado St., Pasadena 1, California.
50. Dr. Samuel R. Snodgrass, (Margaret) Univ. of Texas Medical Branch, Galveston, Texas.
51. Dr. Homer S. Swanson, (La Myra) 384 Peachtree St., N. E., Atlanta 3, Georgia.
52. Dr. William H. Sweet, (Mary) Massachusetts General Hospital, Boston 14, Massachusetts.
53. Dr. Alfred Uihlein, (Ione) Section on Neurological Surgery, Mayo Clinic, Rochester, Minnesota.
54. Dr. A. Earl Walker, (Terrye) Johns Hopkins Hospital, Division of Neurological Surgery, 601 N. Broadway, Baltimore 5, Maryland.
55. Dr. Exum Walker, (Frances) 133 Doctors Bldg., Atlanta 3, Georgia.
56. Dr. Arthur A. Ward, Jr., (Janet) University of Washington School of Medicine, Division of Neurosurgery, Seattle 5, Washington.
57. Dr. Thomas A. Weaver, (Mary) Suite 521, Third National Bldg., Dayton 2, Ohio.
58. Dr. Benjamin B. Whitcomb, (Margaret) 85 Jefferson St., Hartford 14, Connecticut.
59. Dr. Barnes Woodhall, (Frances) Duke University—School Medicine, Durham, North Carolina.





